

## NURSING CARE FOR PEOPLE WITH VENOUS ULCER: CASE REPORT

## ATENCIÓN DE ENFERMERÍA A PERSONAS CON ÚLCERA VENOSA: REPORTE DE UN CASO

## ASSISTÊNCIA DE ENFERMAGEM À PESSOA COM ÚLCERA VENOSA: RELATO DE CASO

<sup>1</sup>Maria Karoline Santos Lima<sup>2</sup>Hevillyn Cecília Ventura Barbosa  
Marinho<sup>3</sup>José Arthur Guimarães dos Santos<sup>4</sup>Kalyne Araújo Bezerra<sup>5</sup>Kleyton Wesllen de Lima Ferreira<sup>6</sup>Raissa Lima Coura Vasconcelos.<sup>7</sup>Fabíola Moreira Casimiro de  
Oliveira

<sup>1</sup>Enfermeira. Residente em Saúde da Família e Comunidade. Faculdade de Ciências Médicas da Paraíba-FCMPB, João Pessoa, Brasil. ORCID – <https://orcid.org/0000-0001-7177-8950>

<sup>2</sup>Enfermeira. Residente em Saúde da Família e Comunidade. Faculdade de Ciências Médicas da Paraíba - FCMPB, João Pessoa, Brasil. ORCID – <https://orcid.org/0000-0002-2299-9869>

<sup>3</sup>Enfermeiro. Residente em Cardiologia. Faculdade de Enfermagem Nova Esperança, FACENE, João Pessoa, Brasil. ORCID - <https://orcid.org/0000-0002-8451-8055>

<sup>4</sup>Enfermeira. Mestranda em enfermagem. Universidade Federal do Rio Grande do Norte (UFRN). Natal, Rio Grande do Norte, Brasil. ORCID: <https://orcid.org/0000-0001-8108-9980>

<sup>5</sup>Enfermeiro. Residente em Pediatria. Escola de Saúde Pública – ESP-PB, João Pessoa, Brasil. ORCID - <https://orcid.org/0000-0002-3314-9560>

<sup>6</sup>Enfermeira. Pós-graduada em Dermatologia, Residente em Saúde da Família e Comunidade. Faculdade de Ciências Médicas da Paraíba, João Pessoa, Brasil. ORCID - <https://orcid.org/0000-0001-6249-1894>

<sup>7</sup>Enfermeira. Mestre em enfermagem. Universidade Federal da Paraíba, João Pessoa, Brasil. ORCID – <https://orcid.org/0000-0003-2983-6621>

**Corresponding Author****Maria Karoline Santos Lima**

Risoldo Ferreira de Lima Rizzo -139 - Planalto Boa Esperança. João Pessoa – PB. Brazil. CEP: 58065137. Contact: +55(83) 98845-4403. E-mail: [karolinelimaenf@gmail.com](mailto:karolinelimaenf@gmail.com)

**Submission:** 08-12-2022**Approval:** 27-12-2022**ABSTRACT**

**Objective:** To report nursing care to patients with venous ulcers and the impact on the user's quality of life. **Methodology:** This is a qualitative study of the case report type with a qualitative design, following the checklist of the Case Report Guidelines (CARE) of the EQUATOR Network. **Results:** In this study, it was possible to observe the healing evolution of a venous ulcer located in the right lower limb, the periodic evaluations under photographic record and therapeutic adherence adopted in each procedural step for better understanding and integral evaluation of the user. **Conclusions:** Thus, upon completing the treatment and follow-up with the user, it was noticed that he presented a significant improvement in his quality of life, improving his social and family life, in addition to a better perception of his self-esteem and self-image.

**Keywords:** Case reports; Venous Ulcer; wound Healing; Nursing Assistance.

**RESUMEN**

**Objetivo:** Relatar los cuidados de enfermería a pacientes con úlceras venosas y el impacto en la calidad de vida del usuario. **Metodología:** Se trata de un estudio cualitativo del tipo reporte de caso con diseño cualitativo, siguiendo la lista de verificación de las Directrices de Reporte de Casos (CARE) de la Red EQUATOR. **Resultados:** En el presente estudio fue posible observar la evolución de la cicatrización de una úlcera venosa localizada en miembro inferior derecho, las evaluaciones periódicas bajo registro fotográfico y la adherencia terapéutica adoptada en cada paso del procedimiento para una mejor comprensión y evaluación integral del usuario. **Conclusiones:** Así, al finalizar el tratamiento y seguimiento con el usuario, se percibió que presentaba una mejora significativa en su calidad de vida, mejorando su convivencia social y familiar, además de una mejor percepción de su autoestima y Auto imagen.

**Palabras clave:** Informes de Casos; Úlcera Venosa; Cicatrización de la Herida; Asistencia de Enfermería.

**RESUMO**

**Objetivo:** Relatar a assistência de enfermagem ao paciente com úlcera venosa e o impacto na qualidade de vida do usuário. **Metodologia:** Trata-se de um estudo qualitativo do tipo relato de caso com delineamento qualitativo, seguindo a lista de verificação da Case Report Guidelines (CARE) da EQUATOR Network. **Resultados:** No presente estudo foi possível observar a evolução cicatricial de uma úlcera venosa localizada no membro inferior direito, às avaliações periódicas sob registro fotográfico e adesão terapêutica adotada em cada etapa processual para melhor compreensão e avaliação integral do usuário. **Conclusões:** Assim, ao concluir o tratamento e acompanhamento com o usuário percebeu-se que, o mesmo apresentou melhora significativa da sua qualidade de vida, melhorando o seu convívio social e familiar, além de melhor percepção sob sua autoestima e autoimagem.

**Palavras-chave:** Relatos de Casos; Úlcera Venosa; Cicatrização de Feridas; Assistência de Enfermagem.



## INTRODUCTION

Chronic venous ulcer is considered the most common among other wound etiologies, being considered a public health problem due to its complexity and chronicity. Venous ulcers are characterized as a result of valvular incompetence associated or not with venous flow obstruction, they are lesions that have the healing process stagnated for six weeks or more, these wounds have a long duration, are recurrent and for having slow healing, in months or years, leads to damage to the quality of life of the patient and causes high costs for treatment <sup>(1)</sup>.

Venous ulcers affect approximately 1 to 2% of the world's population and, in Brazil, they represent the 14th cause of temporary absence from work and the 4th greatest cause of definitive absence from work, since about 70 to 90% of varicose ulcers affect the lower limbs <sup>(1)</sup>.

Given the above, the impacts generated by venous ulcers are not only linked to the economic factor, but also to the physical and psychosocial aspects. There are many negative consequences generated by the lesion, such as difficulty in socializing, depression problems, anxiety, anger, shame, interfering with the state of balance, self-image, self-esteem, self-care, and consequently the Quality of Life (QL) of the individual and his family, which is a relevant phenomenon for health care <sup>(2)</sup>.

The frailty of the individual with chronic wounds is a predominant trend in these cases, therefore, emotional support should be considered a priority, favoring autonomy in making decisions about the problems triggered

by the injury. However, the impact on the QL of people with wounds is not always easy to measure by health professionals, which generates greater complexity and hinders the care provided <sup>(2,3)</sup>.

In this sense, health professionals play a key role in assisting a person with a chronic venous ulcer, since they work to reduce the impacts that the disease imposes on the affected person, as well as in the search for health promotion and disease development prevention <sup>(3)</sup>.

It is noteworthy that the role of nurses in caring for people with wounds is regulated by the resolution of the Federal Council of Nursing (COFEN) No. 0567/2018, which provides for the role of the nursing team in the care of patients with wounds <sup>(4)</sup>. Therefore, the nurse is responsible for autonomy and responsibility in all decision-making, as well as, agreement with the multidisciplinary team in monitoring during the whole process of care provided to the person with a wound <sup>(1)</sup>.

It is essential to emphasize the importance of nurses in the care of people with wounds, however, often the care is based on weak evidence that does not meet the information and conduct accurately and scientifically validated. The products on the market have been innovating and developing, seeking effectiveness in the treatment of wounds, which requires technical and scientific training for nurses to better evaluate and guide the care plan consistently with the current situation of the user. <sup>(5)</sup>.

Given the considerations mentioned above,

the question is: How is the nurse's assistance performed to a chronic venous ulcer carrier, and what is the importance of the nurse's qualification in wound healing? What are the impacts that the chronic wound caused on the quality of life of the user of this study? This study has a general objective: to report the nursing care provided to patients with venous ulcers and the impact on the user's quality of life.

## METHODS

This is a qualitative case report study with a qualitative design, following the EQUATOR Network Case Report Guidelines (CARE) checklist<sup>(6)</sup>. Case reports describe a situation in order to understand and interpret the different phases of the case<sup>(7)</sup>.

The study was developed from a case of chronic venous ulcer in a user belonging to the Health District (HD) IV, in the municipality of João Pessoa, in the state of Paraíba. Data collection was performed through photographic records recorded on a single cell phone during the whole process of lesion monitoring aiming to analyze the evolution of the wound, plus information contained in the family medical record, specifically the forms used in nursing care.

In addition, a structured questionnaire prepared by the researchers was applied in order to collect socioeconomic information, namely: gender, age, color/race, marital status, religion, education, profession, occupation, retirement, family income, who lives with, children, use of medications, diagnosis of hypertension, diabetes

or some other pathology.

To complement the data collected, a survey of articles was carried out through the review method about chronic venous ulcers and the role of nursing professionals in the care of people with wounds, conducted by the authors, performed searches in databases and virtual libraries, such as Scielo, Lilacs, Medline, Pubmed, Cinahl, among others.

This research offered predictable risks, however minimal, that are related to physical, mental, and/or spiritual discomfort which can be mentioned embarrassment and/or sadness by raising unpleasant memories about the physical suffering before the clinical case. To minimize and/or avoid such risks, the researcher maintained privacy, discretion, respect, and emotional support during all the stages of the study, respecting the participant's will and desire to remain or give up their participation at any time during the study.

It is noteworthy that this study met the ethical precepts, meeting the resolution No. 466/2012, of the National Health Council CNS/MS/BRASIL and the principles evoked by the Code of Ethics of Nursing Professionals - Resolution of the Federal Council of Nursing - COFEN No. 564/2017 regarding confidentiality, privacy, and consent of the participant.

The report was reviewed by the Ethics Committee of the Faculdade de Ciências Médicas da Paraíba/ FCOMPB under CAAE: 60807922.6.0000.5178 and approved by opinion number 5.617.081.

## RESULTS

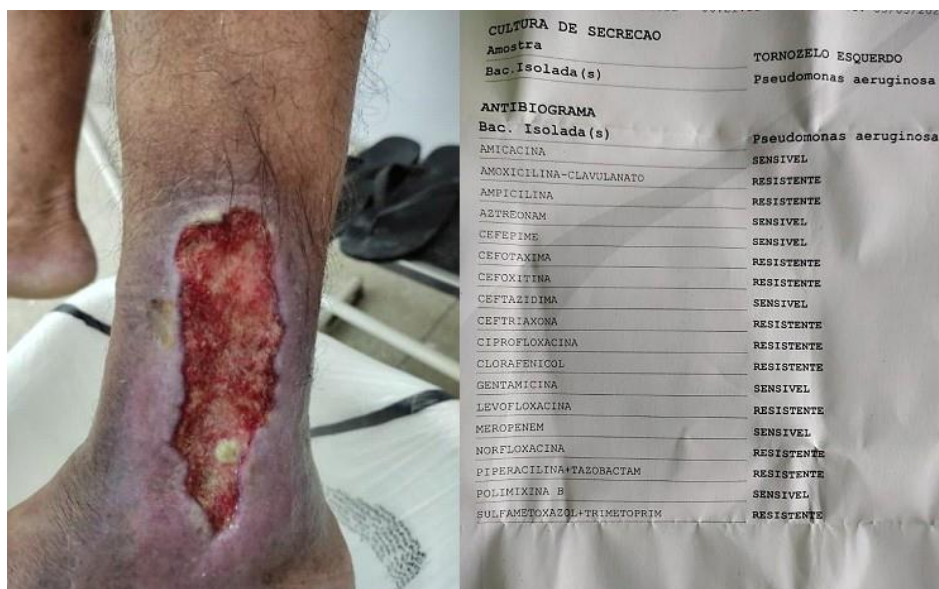Patient, A.B.S., male, 72 years old, living in the city of João Pessoa in the state of Paraíba, father of a 40-year-old daughter, divorced, living with his current partner. He is a bricklayer and carpenter but currently works repairing bicycles. He has incomplete elementary school education, is retired, with a family monthly income of one minimum wage, self-declared white, and follows the Catholic religion. He denies alcoholism and smoking.

As comorbidities, he has Systemic Arterial Hypertension (SAH) and Type II Diabetes Mellitus, both pathologies discovered by the user approximately 15 years ago. He takes Losartan 50mg and Captopril 25mg, as well as NPH

insulin.

The user seeks the family health unit complaining of pain in the right lower limb and difficulty walking due to a lesion in the limb that had remained open for over four years. He claims to have initially arisen from a rejection of the plate placed on the limb after a car accident, having undergone several topical treatments, analgesic medications, and antibiotics, but without success. At the first evaluation, he was anxious, apprehensive, and collaborative, with a face of pain, but eupneic, hypotensive, and afebrile and had normal heartbeat rate and color.

**Figure 1** - Chronic venous ulcer at first evaluation, presence of sphacel in the bed, hyperemia, and edema in the limb with a culture of the lesion which resulted in *Pseudomonas Aeruginosa*.



Source: Author's personal file, 2022





Lesion located in the right lower limb (RLL), approximately 15cm in diameter, with presence of pulse in the area of the tibia, posterior and pedial, signs of inflammation (pain, redness, heat, edema, hyperemia), perilesional skin presenting ochre dermatitis, irregular and macerated edges. The bed of the lesion has sphacelus and granulation tissue, high exudate of greenish-yellow color with the presence of a characteristic odor.

After the initial evaluation of the lesion, wound cleaning was performed according to the following steps: cleaning with saline 0.9%, antiseptic soap with polyhexanide (PHMB), application of primary dressing with calcium alginate and sterile gauze, and as secondary layer compressive therapy with a bandage was used.


The user was instructed to rest and elevate the limb for at least 40 minutes a day to reduce edema, increase fluid intake, and eat adequate and necessary food to aid healing, as well as requesting bacteriological culture of the lesion, pressure mapping, and daily assessment of fasting blood glucose by capillary test for monitoring

The evaluation of the multi-professional team was also requested, which included: a doctor, nutritionists, a pharmacist, and a physiotherapist. The user's diet, body mass index, administration of oral and injectable medications, and the performance of kinetic postural assessments were performed for better understanding, and comprehensive evaluation of the user aiming at reducing factors that delay healing.

**Chart 1** - Evolution of the Chronic Venous Ulcer, cleaning of the lesion, bandage used.

| IMAGE   | LESION  | DATE       | CLEANING                            | COVERAGE  |
|---|---|------------|-------------------------------------|---|
|  | <ul style="list-style-type: none"> <li>- Phlogistic signs</li> <li>- Smears</li> <li>- Maceration of edges</li> <li>- Ochre dermatitis</li> <li>- Granulation tissue</li> <li>- High exudate</li> </ul>                       | 02.08.2022 | SS 0.9% + antiseptic soap with PHMB | Barrier cream (perilymph) + calcium alginate tape + sterile gauze + bandage |
|  | <ul style="list-style-type: none"> <li>- Phlogistic signs</li> <li>- Ochre dermatitis</li> <li>- Maceration of the borders</li> <li>- Granulation tissue</li> <li>- High exudate</li> <li>- Pseudomonas aeruginosa</li> </ul> | 02.22.22   | SS 0.9% + antiseptic soap with PHMB | Barrier cream (perilymph) + calcium alginate tape + sterile gauze + bandage |

|   |   |            |                                     |  |
|---|---|------------|-------------------------------------|--|
|    | <ul style="list-style-type: none"> <li>- Ochre Dermatitis</li> <li>- Maceration of the edges</li> <li>- Granulation tissue</li> <li>- High exudate</li> </ul>   | 03.24.2022 | SS 0.9% + antiseptic soap with PHMB | Barrier cream (perilymph) + calcium alginate tape + sterile gauze + bandage                                |
|    | <ul style="list-style-type: none"> <li>- Ochre Dermatitis</li> <li>- Maceration of the edges</li> <li>- Granulation tissue</li> <li>- High exudate</li> <li>- Acinobacter spp bacteria</li> </ul>                                 | 04.01.22   | SS 0.9% + antiseptic soap with PHMB | Barrier cream (perilymph) + calcium alginate tape + sterile gauze + compressive therapy with bandage       |
|   | <ul style="list-style-type: none"> <li>- Ochre Dermatitis</li> <li>- Approximation of the borders</li> <li>- Increased tissue in the lesion bed</li> <li>- Granulation tissue</li> <li>- Smears</li> <li>- Low exudate</li> </ul> | 04.25.22   | SS 0.9% + antiseptic soap with PHMB | Barrier cream (perihelion) + hyaluronic acid + gauze with PHMB (Kerlix™)+ Unna boot                        |
|   | <ul style="list-style-type: none"> <li>- Ochre Dermatitis</li> <li>- Granulation Tissue</li> </ul>  | 06.05.2022 | SS 0.9% +                           | Barrier cream (perihelion) + hyaluronic acid +   |
|  | <ul style="list-style-type: none"> <li>- Approximation of the borders</li> <li>- Increased tissue in the bed</li> <li>- Low exudate</li> </ul>  |            | antiseptic soap with PHMB           | gaze com PHMB (Kerlix™)+ compressive therapy with bandage  |
|  | <ul style="list-style-type: none"> <li>- Ochre Dermatitis</li> <li>- Epithelialization tissue</li> <li>- Approximation of borders</li> <li>- Flat wound</li> <li>- No exudate</li> </ul>  | 06.06.2022 | SS 0.9% + antiseptic soap with PHMB | Barrier cream (perihelion) + hyaluronic acid + gauze with PHMB (Kerlix™)+ compressive therapy with bandage |
|  | <ul style="list-style-type: none"> <li>- Flat wound</li> <li>- No exudate</li> <li>- No phlogistic signs</li> <li>- 100% healed</li> </ul>  | 07.06.2022 | SS 0.9% + antiseptic soap with PHMB | Barrier cream  |

|   |  |             |  |               |
|---|--|-------------|--|---------------|
|  | <p>- 100% healed<br/>- Given guidelines on skin maintenance.</p> | 07.15. 2022 |  | Barrier cream |
|---|--|-------------|--|---------------|

Acronyms: SS: saline solution; PHMB: polyhexamethylene-biguanide.

Source: Author's personal file, 2022.

## DISCUSSION

Most of the people affected by venous ulcers are male. It was also observed that people over 50 years of age, of both sexes, who have low education and an income equal to or less than one minimum wage are more likely to develop ulcers (8). The increase in cases of venous ulcers is related to the incidence of comorbidities (Systemic Arterial Hypertension (SAH), Diabetes Mellitus (DM), venous insufficiency, and overweight or obesity) in people over 60 years old, as is the case in the study user, who has SAH, type 2 DM, venous insufficiency, is overweight, and is 72 years old. (9-10).

When evaluating the user's injury, one can observe characteristics of Chronic Venous Insufficiency (CVI), highlighting skin hyperpigmentation, edema, and pain, among others, the observation of these signs being essential for a better decision of therapeutic measures (9).

Most of the time, ulcers get healed over a long period, and it can be even longer when an infectious process occurs because it is associated with an increase in the healing period of the wound. Infections in leg ulcers are caused by

Gram-positive and Gram-negative bacteria, often resulting in the need for hospitalization.

The most common bacteria in wounds are *Staphylococcus aureus*, *Pseudomonas aeruginosa*, *Enterococcus faecalis*, *Klebsiella pneumoniae* and *Escherichia coli*, which, despite being common, are difficult to treat, because when they develop they are resistant to one or more antibiotics, becoming a challenge for assistance and prolonging hospitalization. (11)

The culture for identification of microbial isolates becomes extremely necessary since it enables nurses to have a more critical view of chronic wounds, showing the possibility of bacterial resistance, which can cause increased treatment time and institutional costs. In this sense, three techniques that are considered efficient in bacterial identification stand out, biopsy, needle aspiration, and swab; the latter is practical, economical, non-invasive, and guides antibiotic therapy and subsidizes sensitivity tests (11).

In this sense, it is necessary a systematic and structured assessment of the wound bed, identifying factors that may hinder healing. Therefore, we created the mnemonic rule using the acronym TIME, where the T stands for the presence or absence of devitalized

tissue; the letter I stands for the presence of infection or colonization; the letter M stands for moisture imbalance; and the letter E refers to the "edge", evaluation of the wound border. After that, the next steps follow: the process of cleaning the lesion and proper coverage to achieve the desired results <sup>(12)</sup>.

Faced with the variety of products with antiseptic action, it is recommended to search for those with non-toxic actions that can effectively control the bacterial load, reduce biofilm and promote chronic wound healing. Currently, polyhexamethylene-biguanide (PHMB) stands out in the market, which has antiseptic properties acting on cell disruption in gram negative, gram positive, and anaerobic bacteria and in plaque and biofilm formation, being lethal for a wide spectrum of bacteria and has low toxicity for human cells. <sup>(12-13)</sup>.

In clinical practice, among the best-known dressings are alginate-based bandages, which may present several formats of plaques, such as flat and porous, freeze-dried, tape, and string, designed for cavitary wounds. Calcium alginate, or sodium calcium alginate, is derived from brown seaweed, and its main characteristics are absorption of wound exudate with moderate or high exudate, ability to keep the wound bed moist, promote autolytic debridement, hemostasis due to calcium ions, and help contain bleeding <sup>(11)</sup>.

Another product that has been widely studied and that was used in the case reported is hyaluronic acid, a high molecular weight polysaccharide that offers support, volume,

hydration, and tissue elasticity and is present in the connective tissue of the dermis. Its use in wounds is effective because it has a high capacity to retain water, promotes a humid environment suitable for the synthesis of collagen and elastin, favors healing, has an antioxidant, and anti-inflammatory effect, and acts against free radicals, protecting the skin <sup>(13)</sup>.

A treatment option in cases of venous ulcer is compressive therapies, which could be elastic (stockings, bandages, or multi-layers), inelastic (unna boot), or intermittent pneumatic. The boot stands out for its high effectiveness in the treatment of venous ulcers, allowing compression on the affected limb, which facilitates blood return and promotes therapeutic effects due to its composition <sup>(14)</sup>.

This technique was developed in 1896 by the German dermatologist Paul Gerson Unna, and has proven efficient in the treatment of venous ulcers and lymphatic edema. It can be performed by the physician or nurse, and the exchange varies from 3 to 7 days depending on the amount of exudate in the lesion <sup>(15)</sup>. The nurse should be aware of the intensity that will be exerted during the performance of the technique, since it may cause limb tourniquetting and ineffective pressure due to loosening of the bandage, triggering ineffectiveness of treatment <sup>(14)</sup>.

Therefore, the diagnosis and treatment of chronic and infected venous ulcers becomes a challenge for the multidisciplinary team. The team, through clear symptom criteria, and holistic assessment is able to implement timely



assistance that offers adequate treatment <sup>(11)</sup>.

## FINAL CONSIDERATIONS

Considering the observed aspects, it is perceptible the relevance and importance of Nursing regarding the patient's healing process. Nurses are responsible for assisting the individual as a whole, taking into account their weaknesses, whether physical or emotional. In addition, they treat venous ulcers, monitor their evolution, adopt strategies to promote the healing of lesions already installed, and prevent other injuries and relapses, aiming to reduce the discomfort and pain of patients.

Thus, at the end of the treatment and follow-up with the user of this study, it is clear that he presented a significant improvement in his quality of life, improving his social and family life. His self-esteem and self-image were also positively impacted, allowing him to be perceived as an active person in society, putting an end to the cycle of the injury that can last for decades and that directly affects the mental health of the patients.

## REFERENCES

1. Cordeiro JPN, Almeida EIA, Magalhães AKG, Galvão AMN, Carvalho HB, Pitta GBB. Treatment of varicose ulcer with unna boot: Adverse effects arising from lack of knowledge in its maintenance. *RSD [Internet]*. 2022 [cited 2022 Nov 28];11(5):e37011527584. doi: <https://doi.org/10.33448/rsd-v11i5.27584>
2. Silva TG, Vasconcelos APL, Ramos EVC, Farias Neto JP. Evaluation of the quality of life of patients with chronic wounds treated at the healing clinic of the University Hospital of Sergipe. Sergipe: *Rev Bras Qual Vida*. 2017;9(3):234-246. doi: <https://doi.org/10.3895/rbqv.v9n3.6704>
3. Ascari RA, Müller GV, Carvalho AS, Weihermann AMC. Venous ulcers and the changes caused in the family structure. *Rev Enferm Atual In Derme*. 2022;96(37):e-021192. doi: <https://doi.org/10.31011/reaid-2022-v.96-n.37-art.1278>
4. Conselho Federal de Enfermagem [Internet]. Resolução COFEN nº 567, de 04 de fevereiro de 2018. Brasília: COFEN; 2018. [citado 2022 Nov 29]. Disponível em: [http://www.cofen.gov.br/resolucao-cofenno-567-2018\\_60340.html](http://www.cofen.gov.br/resolucao-cofenno-567-2018_60340.html).
5. Costa JAS, Pitella CQP, Lopes APR, Caetano LCO, Santos KB. Nursing knowledge in chronic wound management in primary health care settings. *Rev Enferm Atual In Derme*. 2022;96(37):e-021199. doi: <https://doi.org/10.31011/reaid-2022-v.96-n.37-art.1282>
6. Riley DS, Barber MS, Kienle GS, Aronson JK, Von Schoen-Angerer T, Tugwell P, et al. CARE guidelines for case reports: explanation and elaboration document. *J Clin Epidemiol*. 2017;89:218-35. doi: <https://doi.org/10.1016/j.jclinepi.2017.04.026>
7. Casarin ST, Porto AR. Experience Report and Case Study: some considerations. *J. nurs. health [Internet]*. 2021 [citado nov 29];11(2):e2111221998. Disponível em: <https://periodicos.ufpel.edu.br/ojs2/index.php/enfermagem/article/view/21998>
8. Santos FVM, Chagas MPL, Chaves RN. Sociodemographic and Epidemiological Profile of Patients Treated with Unna Boot. *Rev Saúde*. 2020; 7(2):25-40. doi: <http://dx.doi.org/10.12819/rsf.2020.7.2.2>
9. Bernardino LCS, Santos INB, Estrela FM, Soares CFS, Bina GM, Reis RP, et al. Evolution of pressure injury associated with conservative instrumental breakdown by nurses in primary health care. *Rev Enferm Atual In Derme*. 2021;95(34):e-021092. doi: <https://doi.org/10.31011/reaid-2021-v.95-n.34-art.1095>
10. Fadel ARMC. Caracterização do perfil epidemiológico e demográfico de pacientes com Lesões de membros inferiores: estudo de

prevalência em um hospital privado de Minas Gerais. Minas Gerais. monografia (Especialização em Enfermagem) - Universidade Federal de Minas Gerais; 2020.

11. Garcia TF, Silva PGA, Barcelos BJ, Miranda MGR, Alonso CS, Abreu MNS, et al. Criteria to evaluate the quality of alginate wound dressings. *Rev Bras Enfermagem*. 2021;74(4):e20201091. doi: <https://doi.org/10.1590/0034-7167-2020-1091>

12. Santos MC. Efetividade do poli-hexametileno-biguanida (PHMB) na redução do biofilme em feridas crônicas: revisão sistemática. Paraná. dissertação (Mestrado em Enfermagem) - Universidade Federal do Paraná; 2017.

13. Silva APR, Silva JC, Campos RMB, Abreu AM. The use of Hyaluronic Acid for wound healing: integrative literature review. *RSD*. 2022;11(5):e58711528581. doi: <https://doi.org/10.33448/rsd-v11i5.28581>

14. Motta ALC, Oliveira EC, Silva GC. The role of nursing in the application of Unna Boots for treatment of venous injuries. *Brazilian Journal of Development*. 2022;8(9):61671-9. doi: 10.34117/bjdv8n9-084

15. Cardoso LV, Godoy JMP, Godoy MFG, Czorny RCN. Compression therapy: Unna boot applied to venous injuries: an integrative review of the literature. *Rev Esc Enferm USP*. 2018;52:e03394. doi: <http://dx.doi.org/10.1590/S1980-220X2017047503394>

### Authors' contributions

Maria Karoline Santos Lima: contributed substantially to the conception and/planning of the study. Obtaining, analyzing and interpreting data

Hevillyn Cecília Ventura Barbosa Marinho: Obtaining, analyzing and interpreting data José

Arthur Guimarães dos Santos: Writing and/critical review and final approval of the published version

Kalyne Araújo Bezerra: contributed substantially to the conception and planning of the study. Obtaining, analyzing and interpreting data

Kleyton Wesllen de Lima Ferreira: Writing and/critical review and final approval of the published version

Raissa Lima Coura Vasconcelos: Writing and/critical review and final approval of the published version

Fabíola Moreira Casimiro de Oliveira contributed substantially to the conception and/planning of the study. Obtaining, analyzing and interpreting data Development: there is no development institution

**Fomentation:** there is no development institution

**Scientific Editor:** Francisco Mayron Morais Soares. Orcid: <https://orcid.org/0000-0001-7316-2519>

**Associate Editor:** Edirlei Machado dos-Santos. Orcid: <https://orcid.org/0000-0002-1221-0377>